

Pathology of the testicle after long-term anabolic steroid treatment in a thoroughbred horse from Venezuela

Abelardo Morales Briceño, Francisco García, Mario Rossini, Gerardo Campos, Victor Bermúdez.
Department of Veterinary Pathology, Faculty of Veterinary Science
Central University of Venezuela Maracay, Aragua State Venezuela.
Autor Corresponsal: Abelardo Morales Briceño Email: aamorales13@gmail.com
Department of Veterinary Pathology, Faculty of Veterinary Science
Central University of Venezuela Maracay, Aragua State Venezuela
Recibido: 20/01/2011 Aceptado: 30/03/2011

Abstract

The aim of this study was to describe a case of pathology of the testicle after long-term anabolic steroid treatment in a Thoroughbred horse. We study an equine Thoroughbred with cryptorchidism from Venezuela, male of 5 years old. With history of lameness chronic and subfertility. Necropsy was performed and samples of testicle tissue were collected. The tissue samples were fixed in formalin and processed by conventional H&E techniques. Additionally, the special staining procedure of Tricromico de Gomory and Blue VonKossa were also carried out. Samples of blood and urine were recollected for toxicological by competitive ELISA. The left testicle was diameter testicle 6cm. and cryptorchidism (testicle right). Macroscopic were observed bilateral fibrosis parenchyma testicle and atrophic. The histological study revealed atrophy of seminiferous tubules and interstitial fibrosis increases in collagen fibres in the lamina propria of seminiferous tubules and testicular interstitium. Lamina propria surrounding atrophic tubules was thickened by an increase in collagen type IV and elastic fibres and by proliferation of bizarre myoid cells. Basal lamina was also thickened but had decreased for collagen type IV. Special stain Tricromico de Gomory (+) showed fibrosis interstitium severed and VonKossa (-) no evidence mineral. Toxicological studies allowed the detection of boldenona and dexamethasone generic in blood and urine samples. To conclude, we detected the presence of pathology of the testicle associated a after long-term anabolic steroid treatment in a Thoroughbred horse.

Introduction

The disgenesis reproductive is a severed problem in horse's athletes. Atrophy of seminiferous tubules and interstitial fibrosis are frequently observed in aged horses^{5,6,7,9}. The testicular degeneration is caused by processes such as cryptorchidism and the inflammatory processes³. Many pathological changes such as degeneration of spermatogonia and Sertoli cell, and atrophy and fibrosis of seminiferous tubules with hyalinosis have been reported⁵. Investigations carried out during the last years indicate that COX2 and PGs may play key roles in testicular patho-physiology⁷. Anabolic steroids (ABS) are illegally used for anabolic purposes in humans, horses and cattle⁴. The aim of this study was to describe a case of pathology of the testicle after long-term anabolic steroid treatment in a Thoroughbred horse.

Materials and Methods

We study a equine Thoroughbred male of 5 years old in the National Race Track "La Rinconada" Caracas-Venezuela. The equine present history of lameness chronic and subfertility. Necropsy was performed and samples of testicle tissue were collected. For histological examination, samples were fixed in 10% formalin, embedded in paraffin and cut to 5- μ m sections and processed by conventional H&E techniques^{1,2}. Additionally, the special staining procedure of Tricromico de Gomory and Blue VonKossa were also carried out^{1,2}. Samples of blood and urine were recollected for toxicological by competitive ELISA, specific Boldenone ELISA Kit (Cat.N.FA650 TECNA); Nandrolona: Nortestosterona ELISA Kit (BIO K 208 BIO Diagnostic) y Dexametasona: Dexamethasone ELISA Kit (101519 BIODIAGNOSTIC)¹¹.

Results

The right testis showed signs of cryptorchidism. The size of the left atrophied testis was 6 x 2.5 x 2 cm. The scrotum of this horse had swollen to a thickness of approximately 8cm. and adhered to the tunica vaginalis. A sagittal section of the testis

reveled fibrotic interstitium. Histologically the seminiferous tubules consisted of vacuolated, severed atrophied and scattered Leydig cells and fibrosis interstitium severed (Figure 1). Proliferated spindle cells with fibrogenesis positive a Tricromico de Gomory (+) and Vonkossa (-) (Figure 2). Leydig cells and collagen fibers had increased. There was no spermatic cell in the seminiferous tubules and only Sertoli cells with deposition of brown granules of lipofuscin remained. Toxicological studies in blood and urine samples allowed the detection of boldenona 18 ng/ml and dexamethasone generic 7ng/ml.

Table 1.- Results of toxicological analysis by ELISA competitive of samples of blood and urine in an equine studied.

Blood 60ml	Boldenona 16ng/ml	Dexamethasone 5ng/ml
Urine 300ml	18ng/ml	7ng/ml

Figure 1. Testicle of horse: the seminiferous tubules consisted of vacuolated, severed atrophied and scattered Leydig cells and fibrosis interstitium severed (hematoxylin and eosin method 20X).

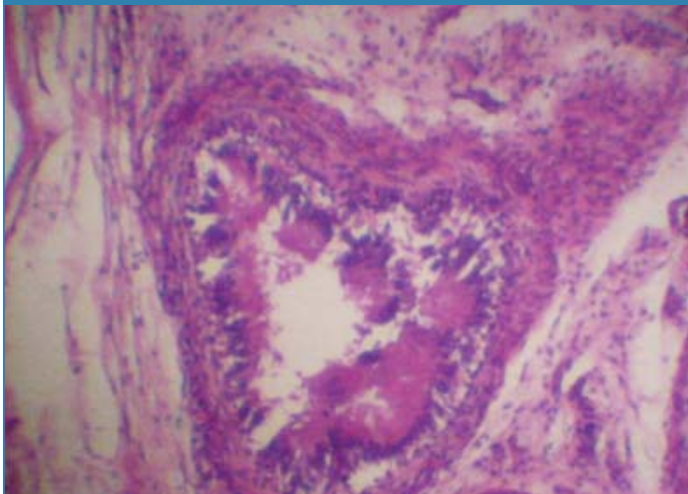


Figure 2. Testicle of horse: Proliferated spindle cells with fibrogenesis positive a Tricromico de Gomory (+); Leydig cells and collagen fibers had increased. (Tricromico de Gomory 20X).

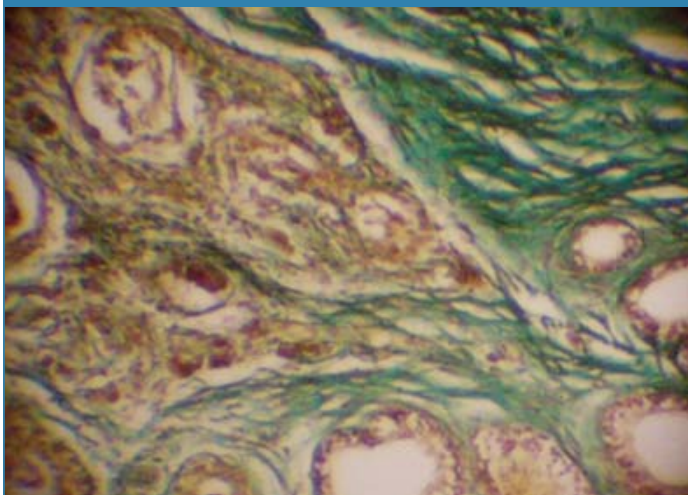
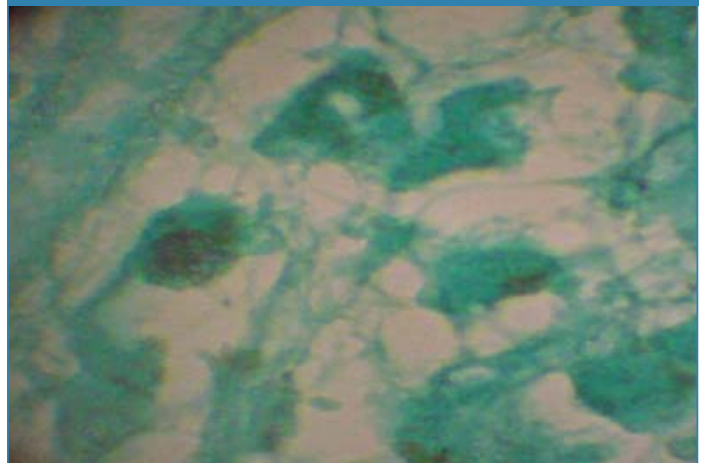


Figure 3. Testicle of horse: Proliferated spindle cells with fibrogenesis negative a Von kossa (-); Leydig cells and collagen fibers had increased. (Von kossa 40X).



Discussion

Testicular fibrosis is considered to be a pathway leading to hypospermatogenesis^{3,5,8,10}. The left testis frequently lags as much as 6 cm behind the right testis in descent, so is more likely to be locked in the abdominal cavity by fibrosis of the internal ring after birth^{6,9}.

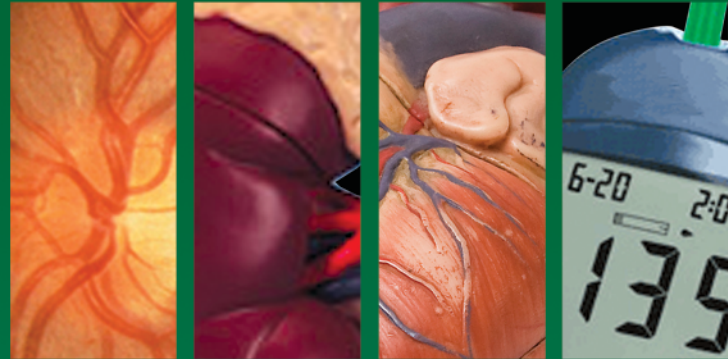Prostaglandins (PGs) are derived from arachidonic acid by the action of the constitutively expressed cyclooxygenase isoenzyme type 1 (COX1) and the inducible isoenzyme type 2 (COX2). Reasons for testicular expression of COX2 and consequences of its actions are not fully known, but cellular and ex-vivo studies provided insights. Mast cells and MAC appear to be involved⁷. Both are significantly increased in the testis of infertile men and correlate with the degree of fibrosis of the tubular wall, a change typically associated with impaired spermatogenesis⁷. The major mast cell product, tryptase, through protease-activated receptors (PAR2) increased the expression of COX2. Subsequently, one of the PGs produced, 15d-PGJ2, acting via the nuclear peroxisome proliferator-activated receptor γ (PPAR γ) was found to induce human fibroblast proliferation⁷. Studies have also shown that all components of the signalling pathway (tryptase-positive mast cells, COX2 and PPAR γ) are present in testes of infertile men and could be responsible for human testicular fibrosis⁷. Testosterone induces COX2 expression and PGF2 α production, but COX2/PGF2 α inhibits StAR and 17 β -HSD expression and consequently, testosterone production thereby setting a brake on testicular steroidogenesis. This regulatory loop might be of relevance in physiological conditions and/or pathological states⁷. These myoid cells transformed into myofibroblasts. The changes are interpreted as evidence of injured structure and function of the lamina propria and basal lamina and may explain the functional decline of the blood-testis barrier. Myoid cells may play an important role in the progression of testicular fibrosis⁶. Plasma concentrations of endogenous 19-nortestosterone (nandrolone; NA) from racing and nonracing males were 50.2 \pm 5.5 and 71.8 \pm 4.6 pg/mL, respectively¹².

The lesions resembled the effects already observed after the administration of androgen hormones to cattle. Main findings were represented by prostate hypersecretion, increased rate of apoptotic cells and decreased rate of Ki67 positive cells in the germ cell line of treated animals, particularly in boldione group and finally some new features like hypertrophy of the prostate urothelial cells^{4,8,13}. To conclude we reported a case of pathology of the testicle after long-term anabolic steroid treatment in a Thoroughbred horse.

References

1. ALUJA A., CONSTANTINO C. Technical of Necropsy in domestic animals. 2,ed. Mexico: Manual Moderno. 2002.
2. BANKS W. Veterinary Applied Histology. 2,ed.. México. Manual Moderno, 1996.
3. BERGIN W. C., GIER, H. T, MARION G. B. COFFMAN J. R. A Developmental Concept of Equine Cryptorchism. Biology of Reproduction August 1, 1970 vol. 3 no. 1 82-92.
4. CANNIZZO FT, ZANCANARO G, SPADA F, MULASSO C, BIOLATTI B. Pathology of the testicle and sex accessory glands following the administration of boldenone and boldione as growth promoters in veal calves. Vet Med Sci. 2007 Nov;69(11):1109-16.
5. DONALD M. Special Veterinary Pathology. 3,ed. USA: Mosby, 1996.
6. FUKUDA TM., KIKUCHI, T., KUROTAKI, T., OYAMADA H., YOSHIKAWA T., YOSHIKAWA. Age-related changes in the testes of horses. Equine Veterinary Journal Volume 33, Issue 1, pages 20–25, January 2001
7. Frungieri M. B. Cyclooxygenase 2 (COX2) and Prostaglandins: Emerging Roles in the Testis. BIOLOGY OF REPRODUCTION 78 : 159. 444. (2008).
8. HIROYASU Y., TOSHIHIDE F., MOTOHIRO KI., TOSHIFUMI O., AND TAKASHI Y. The Relevance of Myoid Cells and Myofibroblasts in Testicular Fibrosis in Two Horses. Journal of Equine Science. 2001 12(1):19-15.
9. JUBB K., KENNEDY P., PALMER N. Domestic animal pathology. 3,ed. Uruguay: Hemisferio Sur, S.R.L. 1984.
10. MORALES A; SÁNCHEZ M; LEAL L; GARCÍA F; LÓPEZ P; RODRÍGUEZ C. Hipersensibilidad tipo I asociada a la administración de nandrolona, boldenona y dexametasona en un equino Pura Sangre de Carrera. Archivos Venezolanos de Farmacología y Terapéutica (AVFT). Vol. 29 no. 2.: 26-28.
11. SOMA LR, UBOH CE, GUAN F, MCDONNELL S, PACK J. Pharmacokinetics of boldenone and stanozolol and the results of quantification of anabolic and androgenic steroids in race horses and nonrace horses. J Vet Pharmacol Ther. 2007 Apr;30(2):101-8.
12. SQUIRES EL, VOSS JL, MAHER JM, SHIDELER RK. Fertility of young mares after long-term anabolic steroid treatment. J Am Vet Med Assoc. 1985 Mar 15;186(6):583-7.
13. WEIDOLF LO, CHICHILA TM, HENION JD. Screening, confirmation and quantification of boldenone sulfate in equine urine after administration of boldenone undecylenate (Equipoise). J Chromatogr. 1988 Dec 9;433:9-21.

Diabetes Internacional



Diabetes Internacional es una revista científica que publica las investigaciones en Nefropatía, disfunción endotelial, cirugía, trastornos psíquicos, patología cardiovascular, retinopatía, nuevas insulinas, fármacos antidiabéticos en proceso de investigación básica y clínica, de nuestro país y América Latina, así como la investigación en otras ciencias básicas como Bioquímica, Fisiología, Fisiopatología e Inmunología en el área de diabetes.

E-mail: diabetesinternacional@gmail.com

www.diabetesinternacional.com

