

# Tityus zulianus and Tityus

## discrepans venoms induced massive autonomic stimulation in mice

E. Trejo, A. Borges, R. González de Alfonso, I. Lippo de Becemberg and M. J. Alfonso\*.

Cátedra de Patología General y Fisiopatología and Sección de Biomembranas. Instituto de Medicina Experimental. Facultad de Medicina. Universidad Central de Venezuela. Caracas. Venezuela.

E. Trejo, Magister Scientiarum en Farmacología y Doctor en Bioquímica.

R. González de Alfonso, Doctora en Bioquímica, Biología Celular y Molecular.

I. Lippo de Becemberg, Doctora en Medicina

M. J. Alfonso, Doctor en Bioquímica, Biología Celular y Molecular

\*Corresponding Author: Dr. Marcelo J. Alfonso.

Sección de Biomembranas. Instituto de Medicina Experimental. Facultad de Medicina Universidad Central de Venezuela. Ciudad Universitaria. Caracas. Venezuela.

Teléfono: 0212-605-3654. fax: 058-212-6628877. Email: hmag5@hotmail.com

Running title: Massive autonomic stimulation by Venezuelan scorpion venoms.

Título corto: Estimulación autonómica masiva producida por los venenos de escorpiones venezolanos.

Recibido: 06/02/0011

Aceptado: 16/09/2011

### Abstract

Venezuelan scorpion envenomation is a public health problem produced by Tityus discrepans (TD) and Tityus zulianus (TZ) species. Patients-envenomed by TD developed gastrointestinal and pancreatic disorders and scorpion accidents involving TZ are associated with high mortality rate, which showed cardiopulmonary clinical disorders may be associated to the high levels of plasma catecholamines levels. This distinctive clinical output seems to be associated to a toxin repertoire diversity, which has been previously demonstrated. Trying to mimic the human-envenomation, some toxicological studies have been performed using TD and TZ venoms in several biomodels such as mice and anesthetized rams. The purpose of this study was to evaluate, in vivo using biomodels (mice), the role of autonomic nervous system (sympathetic) stimulation producing some of the clinical signs, via the catecholamines release, on the patho-physiology of the TZ and TD induced envenomation. Thus, a clinical signs here reported during a period of 1 hr, after a single intra-peritoneal injection of sub-lethal doses of TZ or TD venom, which are related with diarrhea, diaphoresis, intense salivation, dehydration, dyspnea and spasticity in hind limbs. However, these animals did not exhibit vomiting, which is the most frequent human-envenomed TD patients. All animals inoculated with (TD or TZ) venoms developed diarrhea being more pronounced in TD group. Diaphoresis, sialorrhea and dehydration were mainly observed in TD group. Dyspnea and the hind limb spasticity were only developed

in TZ mice. These clinical manifestations (diarrhea, sialorrhea, dehydration and intense salivation) are related to an activation of autonomic nervous system, via an intense release of their related neurotransmitters. Thus, autonomic stimulation (sympathetic) was evaluated following the catecholamine (Nor-Epinephrine)(NE) plasma levels in a function of envenomation time. We found a significant increments at 1 hr, after venom injection, in more than 640% in NE plasma levels for TZ venom while in TD group, around 520% rise in NE concentrations were detected. This massive rise in NE concentrations in TZ and TD-envenomed mice decreased at 6 hrs but remained higher until 24 hrs for both venoms in comparison with Control animals. However, these catecholamines plasma alterations do not explain the dyspnea and hind limb spasticity and more toxicological research should be done to understand the molecular mechanisms related to last clinical signs.

**Abbreviations:** TD: Tityus discrepans, TTX: Tetrodotoxin, TZ: Tityus zulianus, NE, Nor-epinephrine, RyRs: Ryanodine receptors, IpTxA: imperatoxin A, ROS: reactive oxygen species, nAChR: nicotinic acetylcholine receptor (Na<sup>+</sup> channel), (Nav): voltage-dependent sodium channel, MCa: maurocalcine, Tz1: - toxin from Tityus zulianus.

**Key words:** Nor-epinephrine, catecholamine release, Tityus zulianus, Tityus discrepans, scorpion venoms.

### Resumen

El escorpionismo en Venezuela es un problema actual de salud pública producido por las especies de Tityus discrepans (TD) y Tityus zulianus (TZ). Los pacientes que presentan escorpionismo producido por TD desarrollan trastornos gastrointestinales y pancreáticos mientras que los afectados por TZ presentan una alta mortalidad y muestran una sintomatología relacionada a desórdenes cardiopulmonares, los cuales parecen estar asociados a niveles elevados de las catecolaminas plasmáticas. Esta clínica diferente parece estar asociada a una composición distinta de toxinas de dichos venenos, lo cual ha sido previamente demostrado. En un intento de mimetizar o reproducir el escorpionismo en humanos se han realizado estudios toxicológicos con los venenos de TZ y TD utilizando varios biomodelos como son ratones y carneros anestesiados.

El propósito de este trabajo fue evaluar, "in vivo" usando un Biomodelo (ratones), el papel de la estimulación del sistema nervioso autónomo (simpático) para producir algunos signos clínicos, vía la liberación de catecolaminas, en la fisiopatología del escorpionismo producido por TZ y TD. Así, los signos clínicos aquí descritos y observados durante 1 hr., después de la inyección de una dosis sub-lethal de los venenos de TZ y TD, fueron la presencia de diarrea, diaforesis, salivación intensa, deshidratación, disnea y parálisis en las extremidades posteriores. Sin embargo, estos animales no presentaron vómitos, el cual es uno de los signos más frecuentemente observado en los pacientes con accidentes escorpiónicos por TD. Todos los animales inyectados con los venenos de TD y TZ presentaron diarrea especialmente en grupo TD.

La disnea y la parálisis en los miembros posteriores fueron sólo observadas en el grupo de ratones inyectados con TZ. Las manifestaciones clínicas como son diarrea, diaforesis y la salivación intensa están asociadas a una activación del sistema nervioso autónomo, vía, la liberación intensa de los neurotransmisores correspondientes. La activación autonómica simpática fue evaluada siguiendo las concentraciones de catecolaminas (NE) plasmática en función del tiempo después de la inyección del veneno. Nosotros encontramos que existe un aumento dramáticamente significativo a 1 hr después de la inyección del veneno, en las concentraciones de la NE plasmática en un 640% en el caso del veneno de los ratones envenenados con TZ y un aumento de 520% en los niveles de NE en el grupo con veneno de TD. Este aumento masivo en la concentración plasmática de NE descendió a las 6 hrs y permaneció elevada a las 24 hrs para ambos venenos con relación al Control. Estas alteraciones en las concentraciones plasmáticas de las catecolaminas pueden explicar la mayoría de los signos observados pero no la disnea y la parálisis en los miembros posteriores por lo cual mas investigación toxicológica debe ser realizadas para entender los mecanismos moleculares relacionados con estos signos clínicos.

## Introduction

Scorpion envenomation is a public health problem in tropical areas especially in Venezuela. The most serious clinical cases are produced by *Tityus* sp (Buthidae) mainly two Venezuelan species *Tityus discrepans* (Karsch) at north-central Venezuela and *Tityus zulianus* (González-Sponga) located at Zulia, Mérida, and Táchira states at Venezuela western-Andes range, being both species responsible of a high percentage of scorpion envenomation. Patients-envenomed by *Tityus discrepans* developed gastrointestinal and pancreatic disorders as described by Sequera L. et al.<sup>1</sup> and Mota JV. et al.<sup>2</sup>. Toxicological studies have been performed using *Tityus discrepans* (TD) venom in several biomodels. Thus, D'Suze et al. in 1995<sup>3</sup> reported the isolation of four toxic fractions (TdF-I-IV) from the TD venom. They claimed that TdF-I blocked neuromuscular transmission at the postsynaptic membrane; TdF-II produced muscarinic effects such as sialorrhea, dyspnea and depolarized the muscle membrane by opening sodium channels. TdF-III produced acute pancreatitis and TdF-IV prolonged action potentials, suggesting potassium channel blockage.

Other studies in mice reported by Rodríguez-Acosta et al. in 2000, have shown that TD scorpion venom causes ultrastructural alterations of salivary glands<sup>4</sup> and in lung tissue<sup>5</sup> and they suggested that some of the clinical manifestations of TD scorpion envenomation may be related to the ultrastructural lung damage produced by TD toxins venom. D'Suze et al in 2004<sup>6</sup> reported similar respiratory distress findings using anesthetized TD-envenomed rams.

Interestingly; Borges et al. reported in 2000<sup>7</sup>, that scorpion accidents involving *Tityus zulianus*, (TZ) are associated with high mortality rate in children under eight years old. These TZ-envenomed children showed cardiopulmonary clinical disorders as respiratory arrest and death by pulmonary edema as reported by Mazzei de Davila, et al.<sup>8</sup>. Moreover, in biomodels, Borges et al.<sup>9</sup> have reported that TZ venom is able to induce a very intense pancreatic alterations related to an acute pancreatitis in mice-injected TZ venom. Later, Borges et al. described the effects of a novel -toxin Tz1 from TZ on several subtypes of mammalian voltage-dependent sodium channels ( $Na_v$ ) expressed in HEK 293 cells<sup>10</sup>. One the most relevant effect described, in this study was the leftward shift of the half-maximal activation voltage on the  $Na_v1.4$  sodium channel, mainly presents in skeletal muscle.

In patients envenomed with TZ some cardiovascular and pulmonary alterations may be associated to the high levels of human plasma catecholamines as reported by Mazzei de Davila et al.<sup>8</sup>. This last group described a significant increase in nor-epinephrine (NE) plasma levels determined by HPLC. These authors also claimed that these results correlated well with the cardiopulmonary clinical findings. On this sense, similar cardiovascular alterations induced by scorpion venoms (*Buthus occitanus*) in rats, may be due to an increment in the catecholamine plasma levels between 30 and 40 times in animals inoculated with this scorpion venom<sup>11</sup>. These neurotransmitter increments were reversed with the use of anti-sympathetic drugs.

In both (TD and TZ) venoms, the main components of the scorpion venoms are single chain polypeptides, that in relation to the long-chain toxins, there is clear-cut diversity as described by Borges, et al.<sup>12</sup>. The classic biological effect of these scorpion toxins is the ability to interfere with the voltage-dependent sodium channels ( $Na_v$ ) of the mammalian excitable tissues<sup>13</sup>. These sodium channel neurotoxins induce the release of autonomic neurotransmitter, mainly Nor-epinephrine, Epinephrine and acetylcholine, which are responsible for several symptoms and signs presented in clinical scorpion accidents<sup>14,15</sup>. A similar clinical output has been described to the ones described<sup>16</sup> for patients presenting a clinical syndrome related to a pheocromocytoma (a catecholamines releasing tumor).

The purpose of this study was to evaluate, in vivo using biomodels (mice), the role of autonomic nervous system (sympathetic) stimulation, via the catecholamines release, on the patho-physiology of the TZ and TD induced envenomation.

## Materials and Methods

### Scorpions and Venoms

Adult *Tityus zulianus* scorpions were collected near Mesa Bolívar, Santa Cruz de Mora and Tovar, Mérida State, at The Andes region (Western of Venezuela). *Tityus discrepans* scorpions were collected near San Antonio de Los Altos, Miranda State, (North-central region of Venezuela). Scorpions were classified according to the criteria described by González-Sponga<sup>17</sup> and their venoms were obtained by manual stimulation according to Zlotkin and Shulov<sup>18</sup>. Later, this material was lyophilized. Pools of venoms obtained from 50-60 scorpions was reconstituted in small volume of 0.9% NaCl, centrifuged at 12.000xg for 10 min, and protein concentration was determined in the supernatant using bovine serum albumin (BSA) as protein standard as described by Lowry<sup>19</sup>.

### Bio-models.

Mice were employed in all experiments, according to the protocols approved by the Bioethical Animal Care guidelines of Instituto de Medicina Experimental-UCV. Male BALB/C (20-22 g) were used throughout all specific experiments. All rodent animals were bred and housed in standard cage in a room with an ambient temperature of 23°C ± 2°C and 12-hour light-dark cycle. They were fed using standard laboratory chow and had ad-libitum access to filter water. Mice were randomly assigned to control or experimental group and the development of clinical manifestations were complied and recorded by three independent observers. All clinical signs here described are easy to follow by visual observation, except dehydration, which was evaluated by the "skin turgor" sign, as the time required for the skin of the mouse to return to normal position after, being stretched or pinched by the observer. More than 5 sec of elapsed time was considered as "sign of dehydration".

### Preparation of plasma samples

Mice were injected (0.2 ml) intraperitoneally (i.p.) with *Tityus zulianus* or *Tityus discrepans* venoms at a dose of 0.5 mg protein/kg body weight. Such venom concentration is known to produce pancreas structural alterations in the case of *T. discrepans*<sup>4</sup>. This dose is below the DL<sub>50</sub> for *T. discrepans* (2.51 mg/kg) and *T. zulianus* (1.54 mg/kg) venoms as reported by Borges et al.<sup>7,9</sup>.

Control animals were injected with 0.9 % NaCl. Venom-injected mice were divided into four groups (n = 6 per group) and blood by cardiac puncture was obtained at 0, 1, 6 and 24 hrs after injection. Whole blood was centrifuged at 3000xg for 10 min at 4°C and plasma was removed and stored -80°C.

Determination of Nor-epinephrine plasma concentrations by high pressure liquid chromatography (HPLC).

Nor-epinephrine plasma levels were determinate as described by Lima et al.<sup>20</sup> using a reverse phase HPLC system equipped with electrochemical detector. Samples were thawed and diluted 1:6 in 20% sulphosalicylic acid, vortexed and centrifuged at 17.000x g for 20 min. The supernatant was diluted to 1:2 in mobile phase (1mM EDTA; 1 mM citric acid; 0.65 mM Sodium Octyl Sulphate; 7% acetonitrile; 128 mM formic acid; pH 3.4). Subsequently, samples were injected automatically in variable volume between 10 and 100 µl and NE was separated on a Supercosyl LC18 250 x

4 mm column with a flow velocity 1 ml/min (Isocratic pump Waters 600®). Potential between reference and work electrode was +700 mV (Electrochemical detector Waters 464®). The results were analyzed using the external standard method provided by Waters Breeze Program®.

#### Statistical analysis:

All the results are presented as the mean ± standard error. Data analysis performed with ANOVA and Tukey-Kramer post hoc test using the programs Excel® (Microsoft, USA), Graph Pad In Stat® and Prisma® (Science, USA).

## Results

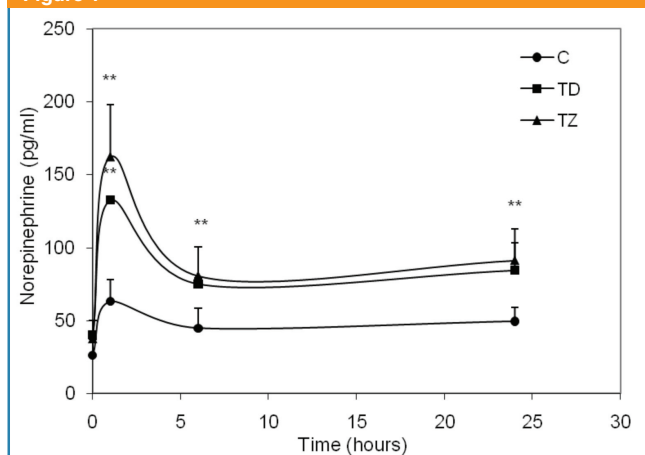
#### Clinical findings:

After a single intra-peritoneal injection of TZ or TD venom (0.5 mg/Kg), mice during a period of 1 hr displayed a variety of clinical signs related with alterations in gastrointestinal, respiratory and skeletal-muscle systems (Table 1). All animals inoculated with scorpion venom (TD or TZ) developed diarrhea being more pronounced in the TD group, which in addition, showed an anal prolapsus. Diaphoresis was more abundant in TD-treated animals. Sialorrhoea and dehydration were observed only in TD group ( $p < 0.01$ ). Dyspnea and the hind limb spasticity were only developed in TZ mice ( $p < 0.01$ ). Most of these clinical manifestations are related to an intense activation of autonomic nervous system probably due to an acute release of their related neurotransmitters.

Plasma catecholamine (NE) levels during TZ and TD envenomation:

The autonomic stimulation was evaluated following the onset of the catecholamine (NE) plasma concentrations in a function of envenomation chronology. Blood samples were taken at different times (0 hr, 1hr, 6hrs, 24 hrs) in the Control, TD and TZ groups. The NE circulating concentration was determined in blood samples taken from envenomed mice and a significant increment ( $p < 0.01$ ) was found in the NE plasma concentrations at 1 h in the TZ group as shown in Figure 1. A slightly but not significant increment in NE concentrations was observed in the Control group, but, in the TZ group, an increment in more than 640% in NE while under TD stimulation, around 520% rise in NE concentrations were detected. At 1hr, after venoms injection, there was a not significant difference between both venoms. These augmentations in NE remained higher after 6 hrs and 24 hrs for both venoms. However, at 24 h both venoms showed values that remained significantly higher in comparison with the Control group ( $p < 0.01$ ).

Figure 1



Time course of plasma nor-epinephrine levels (pg/ml) in mice injected with of TD or TZ venom (0.5 mg/kg). Nor-epinephrine was determined by HPLC coupled to an electrochemical detector as described in Methods. Each point represents the mean ± SEM from (n = 6) animals. ANOVA. 1 hour F (2,15) = 30.73; 6 hrs F (2,15) = 11.29; 24 hrs F (2,15) = 9.87. (\*\*)  $p < 0.01$  vs Control.

Table 1: Clinical findings in mice injected with total venom of *Tityus discrepans* (TD) and *Tityus zulianus* (TZ).

Clinical signs	TD	TZ
	%	%
1. Diarrhea	100	100
2. Diaphoresis	83	50
3. Intense salivation	66	0 **
4. Dehydration	66	0 **
5. Spasticity in hind limbs	0	66 **
6. Dyspnea	0	83 **

Clinical observations were performed after intra-peritoneal injection of 0.5 mg/kg of total venom during a period of 1 hr.

These animals were the same biomodels used for the time dependent evolution (chronology) of the NE plasma determinations shown in Figure 1. Percentage was estimated from observations of three different clinical trained researchers to avoid bias. n = 24 animals for each venom. (\*\*)  $\chi^2 = 77.536$  ( $p < 0.01$ ).

## Discussion

The human clinical features develop as a result of envenomation with Venezuelan scorpion of *Tityus* genus; have been reported<sup>1,2</sup>. This study, here described, is an experimental model (mice), where, we systematically evaluated, the appearance of more relevant clinical signs during 1 hr; after the post-injection of a sub-lethal doses of these two venoms. Some of these effects here described have been reported in both, human and biomodels studies<sup>1,2,6,7</sup>.

We decided to evaluate the early clinical output and progression of the TD and TZ envenomation in mice due to ethical principles. It is very difficult to perform such studies, especially in scorpion-envenomed patients. Thus, using mice, in a more controlled biomodel, we found that the clinical findings observed at 1 hr being the most relevant signs: Diarrhea, diaphoresis, intense salivation, dyspnea and spasticity in the hind limbs as shown in Table 1. In addition, we evaluated the plasma catecholamines (NE) concentrations as an expression of peripheral sympathetic activity as shown in Figure 1.

Trying to understand at the molecular level, the effects of the venoms of scorpion of family Buthidae, producing an intense and massive release of catecholamines (NE) mainly from sympathetic neurons and adrenal gland. This biological activity might be due the fact that these venoms contain and toxins capable of slowing inactivation of voltage-dependent sodium channels ( $Na_v$ )<sup>21,22</sup> that reduce the triggering threshold and produces depolarization inducing the rise of cytoplasmic  $Ca^{2+}$ , which leads to vesicle fusion to plasma membranes and the intense release of the storage-catecholamines in secretory vesicles of adrenal gland to blood stream. Our study shows a significant increment in plasma concentrations of epinephrine (NE), as a result of intense autonomic stimulation. The increase in plasma concentrations of NE is much higher (640% and 520% to TZ and TD respectively) at 1 hr before falling after 6 hrs in both experimental groups. However, at 24 hrs, NE levels in the TD and TZ groups remained significantly above the Control group. Similar results have been reported by Zeghal et al.<sup>11</sup> in studies performed in *Buthus occitanus* envenomed rats, these authors reported a rise in about 300% in plasma concentrations of NE. In TZ-envenomed patients, reported high levels of plasma catecholamines are probably related with some cardiovascular and pulmonary alterations as described by Mazzei de Davila et al.<sup>9</sup>. This last research group found a significant increase in NE plasma levels determined by HPLC. Our results on the NE plasma concentrations demonstrated that it is possible to reproduce in biomodels (mice), at least, some clinical findings described in envenomed-human patients.

Diarrhea, Diaphoresis and intense salivation seem to be the result from initial hyper-stimulation of the autonomic nervous system induced by the toxins present in these venoms. However, dyspnea and spasticity in the hind limbs are difficult to explain as direct effects of autonomic deregulation.

Diarrhea is a sign related to a parasympathetic effect on the intestine smooth muscle, via vagal stimulation producing an increased intestinal

motility<sup>23</sup>. Diarrhea was observed in all of animals inoculated with both, TD or TZ venoms being more intense in mice treated with TD, where additional signs such as dehydration and anal prolapsed were observed.

Vomiting is the most reported clinical sign in TD-envenomated patients<sup>1,2</sup> and similar findings have been described in *Tityus serrulatus*-envenomated patients<sup>14,24</sup>. This sign in humans is related to autonomic activation<sup>25</sup>, which is very difficult to develop in murine models, which is limitation of this biomodel.

Diaphoresis is sign of a postganglionic cholinergic autonomic stimulation, producing excessive sweating, (hyperhidrosis), is a symptom are also characterized by increased sympatho-adrenal activity. Sweat glands are controlled by a cholinergic innervations and an adrenergic component of sweating particularly secretion of the adrenal medulla has been demonstrated<sup>26</sup>. Diaphoresis was displayed at a higher rate in animals inoculated with TD venom. In this sense, D'Suze et al.<sup>3</sup> reported the isolation of 4 toxic fractions (TdF-I-IV) from the TD venom. They claimed that TdF-II produced muscarinic effects such as sialorrhea and dyspnea. Borges et al.<sup>7</sup> described a similar effect in mice inoculated with sub-lethal doses of TZ venom, suggesting that this venom possess toxins with parasympathetic activity, which would be responsible for gastrointestinal and diaphoretic effects.

Interestingly, in this study, an intense salivation (like human Polysialia, Ptyalism) was only observed in animals inoculated with TD. Intense salivation has been also reported for other scorpion venoms of the genus *Tityus* sp., and pharmacological studies have shown that it can be the result of stimulation of the autonomic nervous system. In this sense, Renner et al.<sup>27</sup> in canine models observed an intense flow of saliva after intra-arterial injection of whole venom of three Brazilian species of scorpions: *Buthus quinquestratus*, *Tityus serrulatus* and *Tityus bahiensis*. It is possible that strong cholinergic stimulation would be responsible for cellular changes in salivary glands described in TD-injected mice by Rodríguez-Acosta et al.<sup>4</sup>, which reported ultrastructural alterations of the acinar cells of salivary glands involving severe alterations of the rough endoplasmic reticulum and a depletion of secretory granules. These cellular findings would be responsible for the intense salivation in both envenomed humans and animals.

Dehydration displayed as "skin turgor sign", is a consequence of rapid loss of water or volume depletion, by the diarrhea and diaphoresis, all processes present in TD-envenomated mice and previously discussed. This volume depletion moves interstitial fluid into the vascular bed to maintain circulating blood volume, leading to slackness in the skin's dermal layer.

The presence of dyspnea was observed only in the group of animals treated with TZ. Typically, a symptom or sign of cardiopulmonary dysfunction, in this case, it is difficult or uncomfortable breathing in mice. In TZ envenomation patients, dyspnea occurs mainly as a collection of cardiopulmonary symptoms as reported by Mazzei de Davila et al.<sup>9</sup> in a clinical study showing radiographic findings as the development of pulmonary edema with moderate to severe envenomation. Clinical studies in patients envenomed with other species of the *Tityus* genus described severe respiratory symptoms as adult respiratory distress syndrome (ARDS) and electron microscopy findings compatible with acute lung injury and increased alveolo-capillary membrane permeability<sup>28,29</sup>. Similar lung pathology findings have been described in biomodels such as rats using *Tityus serrulatus* venom by De Matos et al.<sup>30</sup> and Rodríguez-Acosta et al.<sup>5</sup>, in studies with TD venom in mice (5 mg/kg), described ultrastructural changes in lung tissue, specifically denudation of epithelial cells and edema of the basement membrane and they suggested that some of the clinical manifestations of TD scorpion envenomation may be related to the ultrastructural lung damage produced by TD toxins venom. D'Suze et al.<sup>6</sup> reported similar results about respiratory distress using anesthetized rams-envenomed with TD venom. These TD-injected rams developed lungs showing intense necrosis, diffuse injury of the alveolar capillary barrier, interstitial and alveolar fibrin deposits with neutrophil infiltration, which are histopathological findings associated to the development of a severe acute inflammatory process in the walls and alveolar spaces at lungs.

Acute lung injury following envenomation by *Tityus* scorpion species is due in part to activation of the inflammatory response leading to release

of cytotoxic leukocyte-derived products, including cytokines<sup>5</sup> and possibly reactive oxygen species (ROS). In this sense, Borges et al.<sup>31</sup> have reported that TZ venom induced a significantly more potent increase in reactive oxygen species (ROS) production mainly in neutrophils compared to TD venom. No effect was observed on eosinophils, suggesting that TZ venom specifically up-regulates neutrophil intracellular ROS production, which may be an important in vivo target and could have a role to play in the cardiorespiratory complications elicited after envenomation by TZ species.

Interestingly, in our study only the TZ venom induced an increase in the ratio of lung weight/body weight (data not shown) suggesting the existence of lung edema as described by Deshpande et al.<sup>32</sup> in the Indian red scorpion (*Mesobuthus tamulus*) envenomed animals. Apparently, the effects of scorpion toxins on the lungs seems to be due to an indirect mechanism, being lung tissue, a target of a systemic acute inflammation process, which is triggered by the venom as reported by D'Suze et al.<sup>33</sup> and De Matos et al.<sup>34</sup>. These studies suggest that lung damage is caused by vasoactive factors and a limited neurogenic component associated with this acute inflammation.

A unique sign that was observed only in animals inoculated with TZ, was the development of spasticity in the hind limbs. One possible explanation of this unique TZ effect, may be due to a prolonged release of acetylcholine at the mammalian skeletal muscle endplate. D'Suze y col.<sup>3</sup>, using an isolated preparation of amphibian (frogs) sartorius skeletal muscle described variable effects of TD fractions. Hence, Fraction TdF-II produced depolarization and increased both miniature postsynaptic and membrane potentials, this effect was blocked by tetrodotoxin (TTX), implying a sodium channel voltage-dependent. At the same time, Fraction TdF-IV has a similar effect, being a TTX-insensitive and neuromuscular blockers. Moreover, D'Suze et al.<sup>35</sup>, described the development of fasciculations in TD-envenomed anesthetized rams, without an additional explanation about the molecular mechanisms responsible for these fasciculations.

The development of spasticity mentioned above, observed in mice inoculated with TZ, could be also explained on the basis of the experimental results reported by Borges et al.<sup>10</sup>, whom described the biological effects of the novel  $\alpha$ -toxin Tz1 from TZ venom. This group described the effects of Tz1 on several subtypes of mammalian voltage-dependent sodium channels ( $Na_v$ ) expressed in HEK 293 cells. One the most relevant effect described, in this study was the leftward shift of the half-maximal activation voltage on the  $Na_v1.4$  sodium channel, mainly presents in skeletal muscle.

Another possible mechanisms that can explain these fasciculations is the presence of novel toxins in the TZ venom, that can affect the skeletal muscle machinery specially in the  $Ca^{2+}$  release events and depolarization-induced  $Ca^{2+}$  release in skeletal muscle as described by other scorpion toxins, such as imperatoxin. A (IpTxA) from the scorpion *Pandinus imperator*<sup>36</sup> and maurocalcine (MCA) from the scorpion *Maurus palmatus* venom<sup>37</sup>, which have been shown to strongly modify Ryanodine receptors (RyRs)  $Ca^{2+}$  channel properties.

Furthermore; Cheikh et al.<sup>38</sup> have reported that the yellow scorpion *Buthus occitanus tunetanus* (Bot) venom can activate the nicotinic acetylcholine receptor (nAChR), which acting as a  $Na^+$  channel is able to depolarize the end-plate skeletal muscle. Thus, the non-toxic venom fraction (M1) of the *Buthus occitanus tunetanus* (Bot) displays a depolarizing activity following interaction with nAChRs in skeletal muscle cells, inducing a transient increase of  $[Ca^{2+}]_i$ , which could be blocked by a prior application of alpha-Bungarotoxin indicating that a nAChRs is involved.

These biological activities above discussed, might produce alterations in the skeletal muscle contractions, which would explain the spasticity in animals, inoculated with TZ. Further research is needed to understand the molecular basis of these fasciculations, especially in mammalian skeletal muscle cells.

In summary, these clinical findings related to envenomation induced by *Tityus discrepans* and *Tityus zulianus* venoms in intact mice (biomodels) can be explained by the following molecular mechanisms as above discussed.

- 1.-The existence of and **toxins capable of slowing inactivation of voltage-dependent sodium channels (Nav)** in excitable nerve cells, adrenal glands and skeletal muscle end plates.
- 2.-The existence of putative scorpion toxins like-imperatoxin A (IpTxA) and/or maurocalcine (MCa) that affect Ryanadine receptors  $Ca^{2+}$ -release channel at the sarco(endo)plasmic reticulum in mammalian excitable neuronal or non neuronal cells.
- 3.- The existence of putative scorpion toxins like the non-toxic venom fraction (M1) of the *Buthus occitanus tunetanus* (Bot) which induces a transient increase of  $[Ca^{2+}]_i$ , via nAChRs, at skeletal muscle cells.

As discussed, it is important to emphasize that the autonomic stimulation as a single mechanism, is unable to explain all clinical findings in both envenomed-human and biomodels. In this sense, these Venezuelan scorpions venoms might contain novel toxins, which have to be identified, isolated and whose biological activities have to be well established, to understand the molecular aspects related to the pathophysiological mechanisms associated with the acute inflammation process implicate in the envenomation events trigger by these venoms involving human patients.

#### Acknowledgments:

The authors thank to the Fireman Department of San Antonio de los Altos, Miranda State for the specimens of *Tityus discrepans* and the community councils of Santa Cruz de Mora and Tovar, Merida State, for helping in the collection of *Tityus zulianus*. Also to Dr. Lucimey De Lima and MSc. Mary Urbina from the Laboratorio de Neuroquímica del Instituto Venezolano de Investigaciones Científicas (IVIC) for supporting in the plasma catecholamines determinations. This work was supported for a Grant # CDCH PI09006088-2005 (ET) from Consejo de Desarrollo Científico y Humanístico (CDCH-UCV) and Subproyecto 2 (ET, AB, MA) del Proyecto Producción de antivenenos-Misión Ciencia (FONACIT # 2007000672) Ministerio del Poder Popular para la Ciencia, Tecnología e Industrias Intermedias de la República Bolivariana de Venezuela.

#### References

- 1.- Sequera L, Sandoval L, Chávez A. Emponzoñamiento en niños por escorpión *Tityus discrepans*. Arch Venez Puer Pediat. 1993;56: 44-47.
- 2.- Mota JV, Ghersy MT, Bastardo M, Rodríguez J, Duque L, Freytez LA. Emponzoñamiento escorpiónico: Clínica y laboratorio usando antivenina. Bol Hosp Niños (Caracas).1994; 30:35-40.
- 3.- D' Suze G, Sevcik C, Ramos M. Presence of curarizing polypeptides and a pancreatitis-inducing fraction without muscarinic effects in the venom of the Venezuelan scorpion *Tityus discrepans* (Karsch). Toxicon 1995; 33: 333-345.
- 4.- Rodríguez-Acosta A, Pulido-Mendez M, Strauss M, Finol HJ, Rodríguez C, Gonzalez L, Blanco M. Salivary gland ultrastructural alterations in mice injected with *Tityus discrepans* (Buthidae) venom. J Submicrosc Cytol Pathol. 2000; 32: 241-245.
- 5.- Rodríguez-Acosta A, Strauss M, Pulido-Mendez M, Gonzalez L, Rodríguez C, Blanco M. An intent of correlating clinical manifestations and ultrastructural lung changes in mice inoculated with *Tityus discrepans* (Buthidae) venom. J Submicrosc Cytol Pathol. 2001;33: 343-348.
- 6.- D'Suze G, Salazar V, Diaz P, Sevcik C, Azpurua H, Bracho N. Histopathological changes and inflammatory response induced by *Tityus discrepans* scorpion venom in rams. Toxicon. 2004; 44,851-860.
- 7.- Borges A, Arandia J, Colmenares de Arias Z, Vargas AM, Alfonso MJ. Caracterización epidemiológica y toxicológica del envenenamiento por *Tityus zulianus* (Scorpiones, Buthidae) en el Estado Mérida, Venezuela. Rev Fac Med (Caracas). 2002; 25:76 -79.
- 8.- Mazzei de Dávila CA, Dávila DF, Donis JH, de Bellabarba GA, Villarreal V, Barboza JS. Sympathetic nervous system activation, antivenin administration and cardiovascular manifestations of scorpion envenomation. Toxicon. 2002; 40: 1339-1346.
- 9.- Borges A, Trejo E, Vargas AM, Céspedes G, Hernández A, Alfonso MJ. Pancreatic toxicity in mice elicited by *Tityus zulianus* and *Tityus discrepans* scorpion venoms. Invest Clin. 2004; 45: 269-276.
- 10.- Borges, A., Alfonso, M., García, C., Winand, N., Leipold, E., Heine-mann, S. Isolation, molecular cloning, and functional characterization of a novel  $\alpha$ -toxin from the Venezuelan scorpion, *Tityus zulianus*. Toxicon. 2004; 43: 671-684.
- 11.- Zeghal K, Sahnoun Z, Guinot M, Richer C, Giudicelli JF. Characterization and mechanisms of the cardiovascular and haemodynamic alterations induced by scorpion venoms in rat. Fundam Clin Pharmacol. 2000;14:351-361.
- 12.- Borges, A., García, C.C., Lugo, E., Alfonso, M.J., Jowers, M.J., Op den Camp, H.J.M. Long-chain toxin diversity in *Tityus zulianus* and *Tityus discrepans* venoms (Scorpiones, Buthidae): molecular, immunological and mass spectral analyses. Comp. Biochem. Physiol. 2006;142C, 240-252.
- 13.- Gordon D, Martin-Eauclaire MF, Cestèle S, Kopeyan C, Carlier E, Khalifa RB, Pelhate M, Rochat H. Scorpion toxins affecting sodium current inactivation bind to distinct homologous receptor sites on rat brain and insect sodium channels. J Biol Chem. 1996; 271:8034-8045.
- 14.- Amitai, Y. Clinical manifestations and management of scorpion envenomation. Public Health Rev. 1998; 26, 257-263.
- 15.- Gueron M, Ilija R, Margulis G. Arthropod poisons and the cardiovascular system Am J Emerg Med. 2000; 18:708-714. Review.
- 16.- Rodríguez JM, Balsalobre M, Ponce JL, Rios A, Torregrosa NM, Tebar J, Parilla P. Pheochromocytoma in MEN 2A syndrome. Study of 54 patients. World J Surg. 2008; 32 :2520-2526.
- 17.- González-Sponga, M.A., 1996. Guía para identificar Escorpiones de Venezuela. Cuadernos Lagoven, Caracas, 204 p.
- 18.- Zlotkin E, Shulov AS. A simple device for collecting scorpion venom. Toxicon. 1969 ;7: 331-332.
- 19.- Lowry OH, Rosebrough NH, Farr AL, Randall RJ. Protein measurement with the Folin phenol reagent. J Biol Chem.1951;193: 257-265.
- 20.- Lima L, Urbina M. Dopamine and serotonin turnover rate in the retina of rabbit, rat, golfish and *Eugerres plumieri*: Light Effects in golfish and rat. J Neurosci Res. 1994; 39: 595-603.
- 21.- Martin-Eauclaire MF, Céard B, Ribeiro AM, Diniz CR, Rochat H, Bougis PE. Molecular cloning and nucleotide sequence analysis of a cDNA encoding the main beta-neurotoxin from the venom of the South American scorpion *Tityus serrulatus*. FEBS Lett. 1992; 302:220-222.
- 22.- Martin-Eauclaire MF, Céard B, Ribeiro AM, Diniz CR, Rochat H, Bougis PE. Biochemical, pharmacological and genomic characterization of TsIV, an alpha-toxin from the venom of the South American scorpion *Tityus serrulatus*. FEBS Lett. 1994;342:181-184.
- 23.- Bennett A, Whitney B.A Pharmacological study of the motility of the human gastrointestinal tract. Gut; 1966, 7: 307-316.
- 24.- Magalhães MM, Pereira ME, Amaral CF, Rezende NA, Campolina D, Bucarechi F, Gazzinelli RT, Cunha-Melo JR. Serum levels of cytokines in patients envenomed by *Tityus serrulatus* scorpion sting. Toxicon. 1999; 37:1155-1164.
- 25.- Horn CC. Why is the neurobiology of nausea and vomiting so important? Appetite. 2008; 50:430-434. Review.

- 26.- Robertshaw D. Hyperhidrosis and the sympatho-adrenal system. Med Hypotheses. 1979; 5: 317-322.
- 27.- Renner IG, Pantoja JL, Abramson SB, Douglas AP, Russell FE, Koch MK. Effects of scorpion and rattlesnake venoms on the canine pancreas following pancreaticoduodenal arterial injections. Toxicol. 1983; 21: 405-420.
- 28.- Amaral CF, de Rezende NA, Freire-Maia L. Acute pulmonary edema after Tityus serrulatus scorpion sting in children. Am J Cardiol. 1993;71:242-245.
- 29.- Amaral CF, Barbosa AJ, Leite VH, Tafuri WL, De Rezende NA. Scorpion sting-induced pulmonary oedema: evidence of increased alveolocapillary membrane permeability. Toxicol. 1994; 32: 999-1003
- 30.- De Matos IM, Rocha OA, Leite R, Freire-Maia L. 1997. Lung oedema induced by Tityus serrulatus scorpion venom in the rat. Comp Biochem Physiol C Pharmacol Toxicol Endocrinol. 1997;118:143-148.
- 31.- Borges, A., Op den Camp, H.J.M., De Sanctis, J. 2011. Specific activation of human neutrophils by scorpion venom: A flow cytometry assessment. Toxicology in Vitro 25, 358–367
- 32.- Deshpande SB, Alex AB, Jagannadham MV, Rao GR, Tiwari AK. Identification of a novel pulmonary oedema producing toxin from Indian red scorpion (Mesobuthus tamulus) venom. Toxicol. 2005; 45: 735-743.
- 33.- D'Suze G, Comellas A, Pesce L, Sevcik C, Sanchez-de-León R. Tityus discrepans venom produces a respiratory distress syndrome in rabbits through an indirect mechanism. Toxicol. 1999; 37:173-180.
- 34.- De-Matos IM, Talvani A, Rocha OO, Freire-Maia L, Teixeira MM. Evidence for a role of mast cells in the lung edema induced by Tityus serrulatus venom in rats. Toxicol. 2001; 39: 863-867.
- 35.- D Suze, Salazar V, Diaz P, Secvick C, Azpurua H, Bracho N. 2004 istopathological changes and inflammatory response induced by Tityus discrepans scorpion venom in rams. Toxicol 44,851-860.
- 36.- Shtifman, A., Ward, C. W., Wang, J., Valdivia, H. H. and Schneider, M. F. (2000) Effects of imperatoxin A on local sarcoplasmic reticulum  $Ca^{2+}$  release in frog skeletal muscle. Biophys. J. 79, 814–827.
- 37.- Szappanos, H., Smida-Rezgui, S., Cseri, J., Simut, C., Sabatier, J. M., De Waard, M., Kovacs, L., Csernoch, L. and Ronjat, M. (2005) Differential effects of maurocalcine on  $Ca^{2+}$  release events and depolarization-induced  $Ca^{2+}$  release in rat skeletal muscle. J. Physiol. 565, 843–853
- 38.- Cheikh A, Benkhalifa R, Potreau D, Raymond G, El Ayed M, Cognard C. A novel depolarizing activity of scorpion venom fraction M1 due to activation of skeletal muscle nicotinic receptors. Toxicol 2007, 49: 117-122.



# III Congreso 2012



## Sociedad Interamericana de Diabetes

Interamerican Society of Diabetes

# 26 y 27 de Noviembre



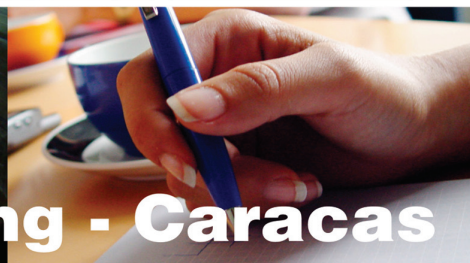**Síndrome  
Cardiometaabólico**

**Archivos  
Venezolanos**  
de Farmacología y Terapéutica

**Latinoamericana  
de Hipertensión**

**Atherosclerosis  
today**

**Diabetes  
Internacional**



## Hotel Eurobuilding - Caracas

www.sidiabetes.com